

Video case report

Gastric cancer: A de novo diagnosis after laparoscopic sleeve gastrectomy

Luigi Angrisani, M.D.^a, Antonella Santonicola, M.D.^b, Paola Iovino, M.D.^{c,*}

^aGeneral and Endoscopic Surgery Unit, San Giovanni Bosco Hospital, Naples, Italy

^bDepartment of Clinical Medicine and Surgery, University Federico II of Naples, Naples, Italy

^cDepartment of Medicine and Surgery, University of Salerno, Salerno, Italy

Received September 13, 2013; accepted September 14, 2013

Keywords: Obesity; Gastric cancer; Sleeve gastrectomy

Epidemiologic studies have suggested that obesity is associated with an increased risk of several cancers [1] such as colon and esophageal adenocarcinomas [2]. A positive association between body mass index (BMI) and gastric malignancies has only been described for adenocarcinomas of the gastric cardia, while the association between BMI and gastric noncardia adenocarcinoma is unclear [3]. A recent systematic review [4] analyzed all reported cases of esophageal or gastric cancers after several bariatric procedures, including vertical banded gastroplasty, gastric band, or Roux-en-Y gastric bypass; but only a case of a lower esophageal adenocarcinoma has been described in a patient who underwent a previous (4 months) sleeve gastrectomy (SG) [5]. To the best of our knowledge, this is the first case of gastric cancer that has occurred after SG.

Case presentation and management

A 51-year-old, severely obese woman with a BMI of 65.1 kg/m² and with obstructive sleep apnea, hypertension, dyslipidemia, and gastroesophageal reflux disease underwent insertion of an intragastric balloon in December 2006 for 6 months. In February 2008 she underwent sleeve gastrectomy (SG) (weight, 147 kg; BMI, 61 kg/m²). The preoperative workup performed routinely before SG, which include upper gastrointestinal endoscopy (UGE), has been previously reported [6,7]. The histologic examination of the

resected stomach revealed a significant infiltration of plasma cells in the lamina propria; the *Helicobacter pylori* test was negative. Further examination with in situ hybridization for κ and λ immunoglobulin light chains was negative for gastric plasmacytoma. No postoperative complications occurred. She lost 34 kg in the first 18 months (weight, 113; BMI, 47; EWL, 31,6%), but in the following months the weight loss stopped. In April 2010 a duodenal switch was planned, but the patient refused. During the following year, the patient did not return for scheduled follow-up visits. In August 2012, the patient presented with complaints of vomiting after ingestion of solid foods, dysphagia, epigastric pain, and asthenia. She underwent a double contrast barium swallow that revealed delayed gastric emptying and pyloric stenosis. A UGE showed a mass in the body and antrum which, on microscopic examination, was a signet-ring cell adenocarcinoma. Computerized tomographic scan of the chest, abdomen, and pelvis with contrast showed a concentric thickening of the wall of the gastric antrum. The liver was slightly enlarged with no focal lesions. Mesenteric and ileocecal lymph nodes were somewhat enlarged. In November 2012 the patient underwent a total gastrectomy (Fig. 1) with a Roux-en-Y intracorporeal esophagojejunostomy with D2 lymphadenectomy and prophylactic cholecystectomy. The histologic examination revealed a poorly differentiated signet-ring cell adenocarcinoma diffusely infiltrating the body, the antrum, and the pylorus. The resection margins were free of tumor, and there was a metastasis in 1/26 of lymph nodes isolated (staging, pT4 a N1; grading, G3). Postoperative adjuvant chemotherapy using capecitabine (Xeloda) and radiotherapy

*Correspondence: Paola Iovino, M.D., Gastrointestinal Unit, Department of Medicine and Surgery, University of Salerno, Via S Allende Baronissi, 84081 Salerno, Italy.

E-mail: piolino@unisa.it

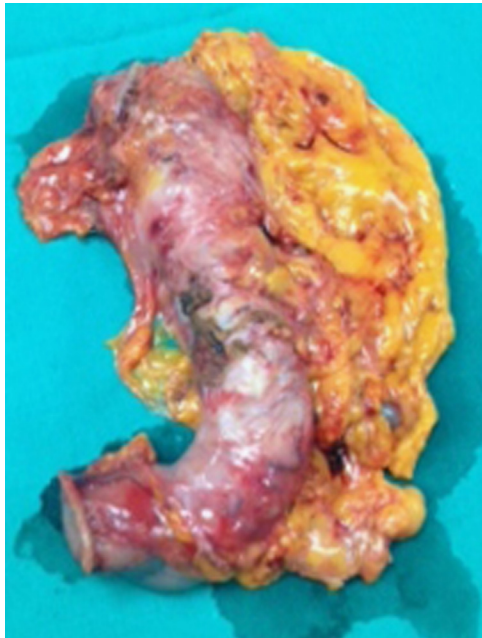


Fig. 1. Resected stomach after total gastrectomy.

(45 Gy + cumulative 180 cGy in fractions) was performed after surgery. At 8 months of follow-up (July 2013), the patient was still disease-free, and her weight was stable.

Discussion

Gastric cancer has become a relatively rare cancer in North America, Northern Europe, and Western Europe [8]. The decline in gastric cancer mortality rate is mainly attributed to a declined prevalence of *H. pylori* infection, but also to an improved diet, including diet variety and better food preservation [9]. To the best of our knowledge, a positive association between BMI and gastric malignancies has been previously described only for gastric cardia adenocarcinomas [4]. This is the first case of signet-ring cell adenocarcinoma of the body and antrum of the stomach, which occurred de novo 4 years after SG. The only previous case report of cancer described after SG was a lower esophageal adenocarcinoma diagnosed 4 months after SG in a patient with several known risk factors for developing esophageal carcinoma: smoking, severe obesity, and probably gastroesophageal reflux disease, who did not undergo an endoscopic evaluation before SG [5].

Conclusion

Although the current guidelines do not strongly recommend the UGE before bariatric surgery (Grade D) [10], the present case suggests that a UGE should be mandatory before SG and at scheduled follow-up to allow for an early diagnosis and better management of concomitant or de novo diseases.

Appendix A. Supplementary Materials

Supplementary data associated with this article can be found in the online version at doi:10.1016/j.soard.2013.09.009.

References

- [1] Kaidar-Person O, Bar-Sela G, Person B. The two major epidemics of the twenty-first century: obesity and cancer. *Obes Surg* 2011;21:1792–7.
- [2] Renehan AG, Soerjomataram I, Leitzmann MF. Interpreting the epidemiological evidence linking obesity and cancer: a framework for population-attributable risk estimations in Europe. *Eur J Cancer* 2010;46:2581–92.
- [3] Abnet CC, Freedman ND, Hollenbeck AR, et al. A prospective study of BMI and risk of oesophageal and gastric adenocarcinoma. *Eur J Cancer* 2008;44:465–71.
- [4] Scozzari G, Trapani R, Toppino M, et al. Esophagogastric cancer after bariatric surgery: systematic review of the literature. *Surg Obes Relat Dis* 2013;9:133–42.
- [5] Scheepers AF, Schoon EJ, Nienhuijs SW. Esophageal carcinoma after sleeve gastrectomy. *Surg Obes Relat Dis* 2011;7:11–2.
- [6] Sauerland S, Angrisani L, Belachew M, et al. Obesity surgery: evidence-based guidelines of the European Association for Endoscopic Surgery (EAES). *Surg Endosc* 2005;19:200–21.
- [7] Angrisani L, Cutolo PP, Buchwald JN, et al. Laparoscopic reinforced sleeve gastrectomy: early results and complications. *Obes Surg* 2011; 21:783–93.
- [8] Bertuccio P, Chatenoud L, Levi F, et al. Recent patterns in gastric cancer: a global overview. *Int J Cancer* 2009;125:666–73.
- [9] Bertuccio P, Rosato V, Andreano A, et al. Dietary patterns and gastric cancer risk: a systematic review and meta-analysis. *Ann Oncol* 2013;24:1450–8.
- [10] Mechanick JI, Youdim A, Jones DB, et al. Clinical practice guidelines for the perioperative nutritional, metabolic, and nonsurgical support of the bariatric surgery patient—2013 update: cosponsored by American Association of Clinical Endocrinologists, The Obesity Society, and American Society for Metabolic & Bariatric Surgery. *Obesity (Silver Spring)* 2013;21(Suppl 1):S1–27.